3DReasonKnee: Advancing Grounded Reasoning in Medical Vision Language Models

Sraavya Sambara[1*], Sung Eun Kim[1,2*], Xiaoman Zhang[1], Luyang Luo[1], Shreya Johri[1], Mohammed Baharoon[1], Du Hyun Ro[2], Pranav Rajpurkar[1]
[1]Department of Biomedical Informatics, Harvard Medical School, Boston, MA, USA
[2]Seoul National University Hospital, Seoul, South Korea

Introduction

Current Vision-Language Models (VLMs) struggle with **grounded reasoning** - reasoning about specific 3D anatomical regions in a clinically valid way.

The Problem

Clinical Workflow Mismatch
Clinicians use a "region-first" workflow (locate → assess → grade). Current VLMs lack this fine-grained, localized analysis capability.

Lack of Suitable Data
Major gap in datasets combining 3D volumetric data, precise localization, and expert-annotated reasoning chains.

Our Contribution: The 3DReasonKnee Dataset

494,000+ Data Quintuples

7,970 3D MRI Scans

- **3D MRI Volumes** — High-resolution DESS sequences from knee imaging
- **Diagnostic Questions** — 62 clinically relevant, subregion-specific queries
- **3D Bounding Boxes** — Precise anatomical localization for each question
- **Chain-of-Thought Reasoning** — Step-by-step clinical reasoning pathways
- **MOAKS Severity Scores** — Structured severity assessments for validation

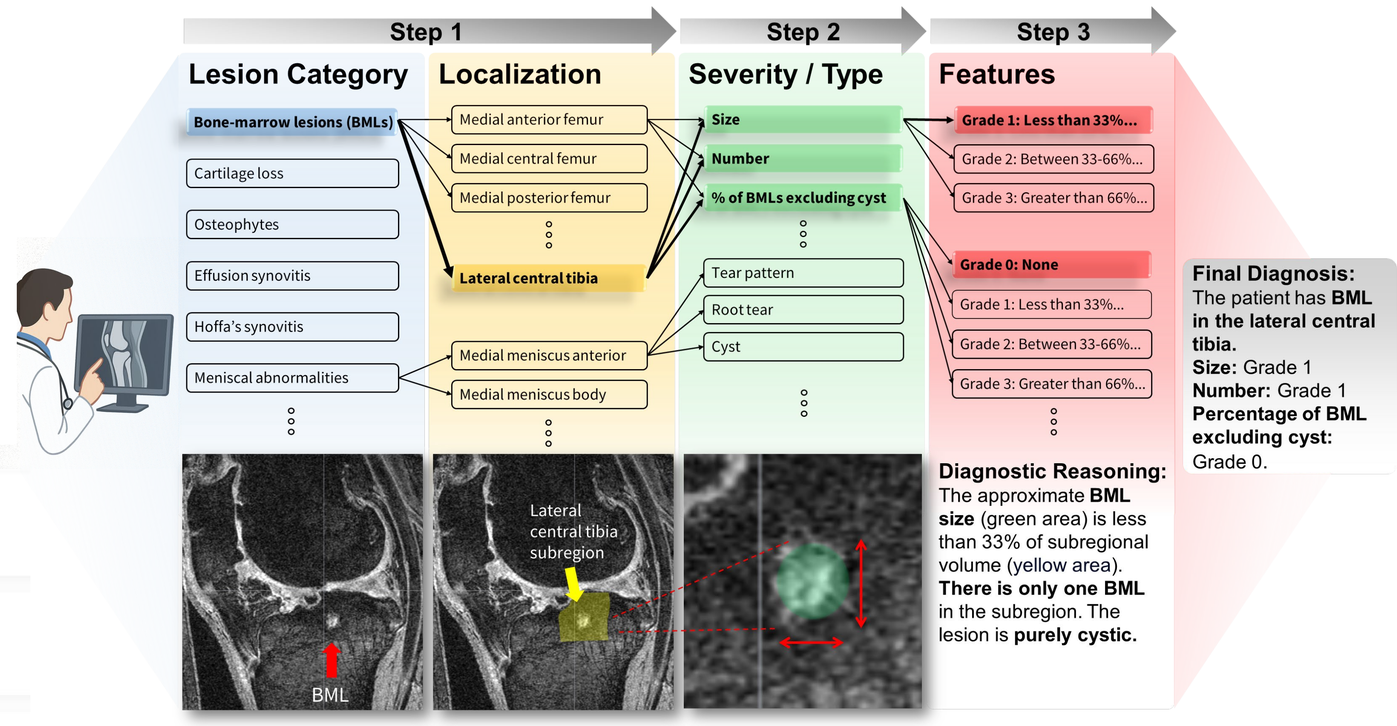

Constructing the 3DReasonKnee dataset using a three-stage pipeline

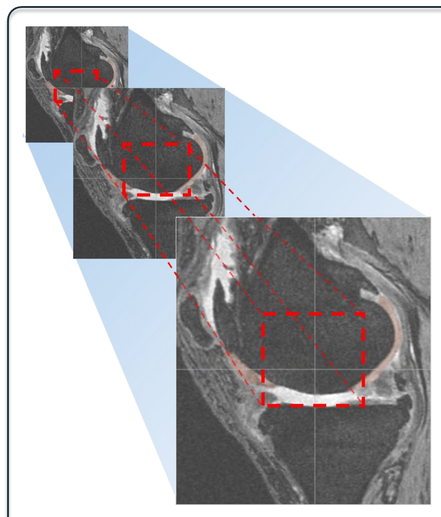

Question: In this DESS MRI, Can you diagnose cartilage lesions in the femur medial central subregion? Provide your reasoning, the bounding box of the femur medial central subregion, and the MOAKS scores for size, and depth.

Reasoning steps:
Step 1 (Lesion category): The cartilage looks gray in the DESS image. It covers the articular surfaces of the bones. I need to see whether the patient's cartilage has a smooth surface, evenly distributed thickness. If there is an abrupt thinning of cartilage, disruption of contour, it implies a cartilage lesion.
Step 2 (Severity / Type): The cartilage lesion is evaluated in two ways, size and depth (percent of full-thickness cartilage loss).
Step 3 (Features): There is loss of cartilage in the subregion. The lesion is over 75% of the surface area of the subregion. There is full-thickness cartilage damage in this area, showing exposed bony surfaces. The full thickness cartilage lesion is over 75% of the cartilage defect
Localization: [77,131,106,235,154,247]

Final diagnosis: Size Grade 3, Depth Grade 3

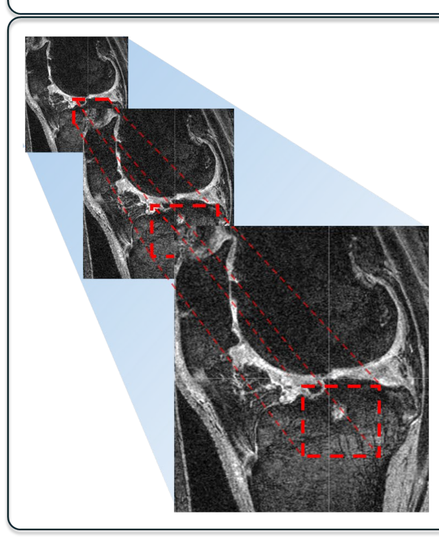

Question: In this DESS MRI, Can you diagnose bone-marrow lesions (BMLs) in the tibial lateral central subregion? Provide your reasoning, the bounding box of the tibia lateral central subregion, and the MOAKS scores for size, number of BMLs, and percent of lesion that is BML.

Reasoning steps:
Step 1 (Lesion category): I should detect hyperintense areas (BMLs) vs. normal low-signal bone; exclude vascular streaks (normal).
Step 2 (Severity / Type): BMLs are evaluated for size, number, and percent of lesion that is BML (excluding cyst).
Step 3 (Features): There is an increased signal intensity in the subregion. Its size is less than 33% of the subregion. The lesions are connected as one. The lesion is purely cystic.
Localization: [25,72,132,189,1,170]

Final diagnosis: Size of BML (including cyst) Grade 1, Number of BML Grade 1, % of lesion that is BML (excluding cyst) Grade 0.

Example of 3DReasonKnee with Chain-of-Thought.

Methods: Building 3DReasonKnee

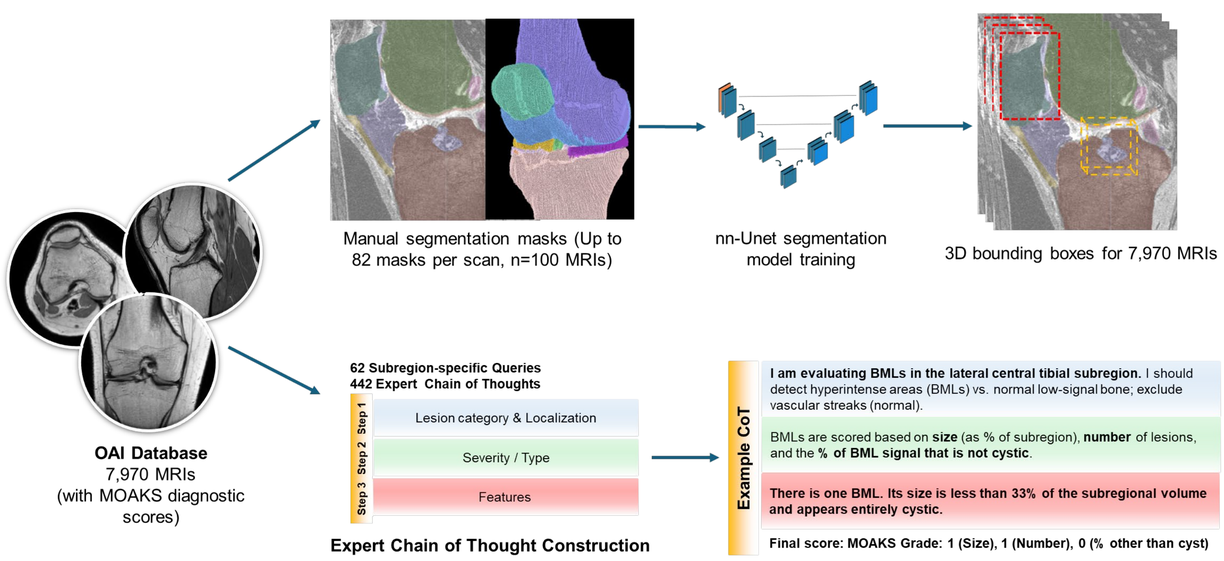

Results

Model	Method	BML	Cartilage	Osteophyte	Meniscus	Others	Overall
Qwen2.5VL-3B	Zero-shot	0.081	0.253	0.251	0.093	0.159	0.158
Qwen2.5VL-7B	Zero-shot	0.642	0.309	0.348	0.347	0.469	0.47
o1	Zero-shot	0.479	0.553	0.353	0.332	0.476	0.477
Qwen2.5VL-3B	Instruction Zero-shot	0.092	0.149	0.253	0.205	0.146	0.146
Qwen2.5VL-7B	Instruction Zero-shot	0.629	0.466	0.342	0.297	0.503	0.504
o1	Instruction Zero-shot	0.635	0.579	0.345	0.391	0.567	0.568
Qwen2.5VL-7B	Instr. Z-shot w/ GT region	0.697	0.549	0.338	0.166	0.563	0.556
Qwen2.5VL-3B	SFT w/o CoT	0.706	0.602	0.345	0.387	0.616	0.613
Med3DVLM	SFT w/o CoT	0.67	0.578	0.33	0.346	0.6	0.596
Qwen2.5VL-3B	SFT w/ CoT	0.667	0.6	0.342	0.34	0.59	0.588
Med3DVLM	SFT w/ CoT	0.671	0.579	0.333	0.343	0.605	0.581

Summary of MOAKS Grading Performance.

- Benchmarking on 3DReasonKnee highlights the difficulty of grounded diagnostic reasoning, with even state-of-the-art VLMs struggling in zero-shot settings.
- Providing ground-truth localization improves diagnostic accuracy, underscoring grounding as a major failure point. Instruction following and SFT improved performance, but subtle categories like Meniscus and Osteophyte remain a challenge.

Model	Patella	Femur	Tibia	Meniscus	ACL	PCL	Synovitis
Qwen2.5VL-3B	0.293	0.275	0.322	0.174	0.299	0.305	0.519
Med3DVLM	0.298	0.314	0.359	0.197	0.319	0.384	0.47

Summary of Anatomical Subregion Localization (IoU).

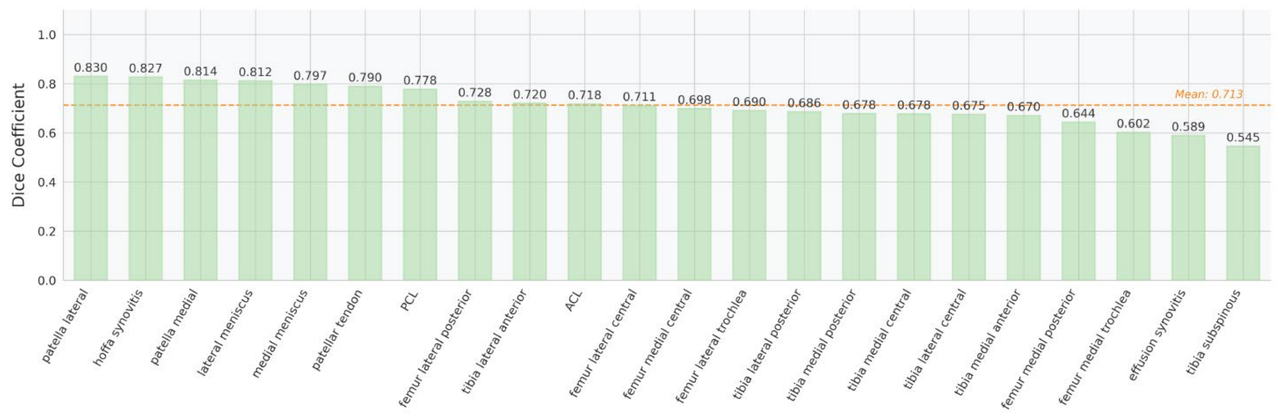

Dice score of the nnU-Net model of all subregions.

Conclusion

•This paper addresses a critical gap in the development of medical VLMs by introducing the first dataset and benchmark for 3D grounded reasoning in medical imaging, pairing richly annotated 3D MRI data with expert reasoning pathways for osteoarthritis severity assessment.
•Experiments show that while instruction-following and supervised fine-tuning improve performance, current VLMs still struggle with accurate grounding and fine-grained reasoning, particularly for subtle lesion categories.
•We believe this work will serve as catalysts for future work on interpretable and clinically trustworthy medical AI.

*These authors contributed equally.

Acknowledgement: This Research was supported by a grant of the Boston-Korea Innovative Research Project through the Korea Health Industry Development Institute(KHIDI), funded by the Ministry of Health & Welfare, Republic of Korea(grant no. : RS-2024-00403047).